

# The Mucosal Lesions on Removable Denture Wearers: A Systematic Revi

*by Acing Habibie Mude*

---

**Submission date:** 07-Jan-2022 12:20PM (UTC+0700)

**Submission ID:** 1738395551

**File name:** Mucosal\_Lesions\_on\_Removable\_Denture\_Wearers.\_A\_Sysrev\_2020.pdf (271.99K)

**Word count:** 2455

**Character count:** 13296

# The Mucosal Lesions on Removable Denture Wearers: A Systematic Review

Mohammad Dharma Utama, Acing Habibie Mude, Muhammad Ikbal, Vinsensia Launardo, Adriani Dachri

Department of Prosthodontic, Faculty of Dentistry, Hasanuddin University, Makassar, Indonesia

**Corresponding Author:** [mohdharmautama@gmail.com](mailto:mohdharmautama@gmail.com)

## ABSTRACT

This systematic review aimed to determine various mucosal lesions that appeared in the oral mucosa of a patient with a removable denture, which reported in some international dentistry journals. The search through PubMed and Wiley was done and resulted in 347 articles. A hundred and ninety-six articles were selected for the title. The abstract selection gathered 23 articles. The selection of full-text was done afterward and resulted in 8 articles with the full-text which met the inclusion criteria and analyzed by the two authors. The mucosal lesions evaluated in this systematic review were some specific lesions that commonly found on the surface of the mucosa or in any tissue level, which varies from benign to malignant, such as hyperplasia, hyperemia tumor, nodules, and ulceration. The diagnosis was denture stomatitis, oral lichen planus, fibroma, peripheral ameloblastoma, and chondroblastic osteosarcoma. The mucosal lesion in patients with a removable denture, such as removable partial denture and the full denture was various. The lesion's existence was influenced by some factors, such as prolonged use of the dentures, the denture condition, and oral hygiene.

**Keywords:** mucosal lesion, removable denture.

## Correspondence:

Mohammad Dharma Utama  
Department of Prosthodontic, Faculty of Dentistry, Hasanuddin University,  
Makassar, Indonesia  
**Corresponding Author:** [mohdharmautama@gmail.com](mailto:mohdharmautama@gmail.com)

## INTRODUCTION

The denture is a rehabilitative effort in patients with tooth loss, either partially or entirely in the oral cavity.<sup>1</sup> The use of dentures in a certain period can provide a change in the condition of the oral cavity, especially the mucosa, in direct contact with the denture. These changes can be in the form of mucosal lesions such as hyperemia, ulceration, edema, to stomatitis.<sup>2</sup> Denture stomatitis causes mild inflammation and mucosal erythema that occur in removable denture base or completely over denture. This condition is often asymptomatic, but when symptoms appear, it may cause a burning sensation, bleeding of mucous, and dryness in the mouth.<sup>3</sup> This review will discuss several mucosal conditions and lesions that manifest in patients' oral cavity using removable denture whose data are obtained from various data search sources.

## METHODS

PRISMA (Preferred Reporting Items for Systematic reviews and Meta-Analyses) is a writing guide used in the preparation of this systematic review. Structured questions are used to focus on a discussion to be achieved.<sup>4</sup> This formal question is called PICO. PICO consists of population, intervention, control, and outcome.<sup>4</sup> PICO as of writing this review are: what mucosal lesions can be manifested in patients' oral cavity using removable dentures? The population and intervention of this review were patients using removable dentures. The comparison or control of this review is the type of lesion that often appears in the patient's oral cavity. In contrast, this review's outcome is data on the types of lesions that appear most frequently, and the response of these lesions based on published articles.

The Pubmed and Wiley database is used as a data search source. This search refers to the literature in English as one of the study protocols. This data search was conducted to identify articles published in dental journals in the past five years. Besides, the article must have a focus on mucosal lesions in removable denture users. Data search needs to use the same keywords in each database, which refers to MeSH (Medical Subject Headings). MeSH in this review is "Removable denture" and "Mucosal lesion." Besides, article search refers to English, the publication period for the past five years, and the type of article. The examples of articles published include original articles and case reports. There are 347 articles obtained from the use of the keywords mentioned earlier. Article selection was done on 347 articles and received 196 articles that were selected through the title. Then the selection continued in the abstract and obtained 23 articles. Then, the selection was done on the 23 articles and found eight articles that have full text and have met the inclusion criteria of this review.

There are several inclusion criteria for preparing this systematic review. The inclusion criteria are the language used in writing the article, the time of publication, the focus of the report, the type of article, and the article's subject. The language used in the article is English. The time of publication is the last five years. The focus of the article is mucosal lesions on denture users. The type of article can be in the form of an original article and a case report. And the subject of the article is human. The authors of this review (AD and DU) use keywords for the article selection process based on the abstract and full-text analysis. The selection process is done separately. This selection begins with the title selection. After getting the predicted titles according to the inclusion criteria, the document is downloaded, then the abstract is selected.

After abstract selection, full text is downloaded for each abstract that is predicted to meet all inclusion criteria. Then, all full text is read, and articles are determined that meet all the inclusion criteria for review and evaluation.

### RESULT

A total of 347 articles were obtained from search results in the database. Data collection gained 343 articles from Wiley and four articles from PubMed. Article selection was done on 347 articles and collected 196 articles that were selected through the title. Then the selection continued in the abstract and obtained 23 articles. Then, the selection was done on the 23 articles and found eight articles that have full text and have met the inclusion criteria of this review. The flow of article selection can be seen in Figure 1.

Mucosal hyperplasia was found in 2 case reports, such as a case report in an article made by Durmaz and Bernardez.<sup>6,7</sup> In a case report made by Drumaz, a 52-year-old woman, had a hyperplasia lesion with a diagnosis of denture-induced fibroma. Whereas in research conducted by Bernardez, hyperplasia lesions were diagnosed as inflammatory fibroma hyperplasia. This hyperplasia condition generally occurs due to excessive pressure on the mucosa caused by dentures.<sup>8</sup> Ulcerated lesions were reported by Lorenzo in 2018. This type of lesion also occurs due to extreme pressure on the denture area that compresses the mucosa. The lesion suffered by this 54-year-old female patient was diagnosed as an erosive oral lichen planus.<sup>9</sup> This lesion was considered a hypersensitivity reaction to acrylic denture components Eliene reported.<sup>10</sup> Nodular lesions in 2018 in Brazil. This lesion was diagnosed as recurrent peripheral ameloblastoma.<sup>11</sup> Priya said tumor lesions in 2018 with a diagnosis of chondroblastic osteosarcoma.<sup>12</sup> Hyperemia lesions published by Carolina, Elisenda, and Lidia in different years and places were diagnosed as denture stomatitis.<sup>13, 14, 15</sup> This condition is widespread in patients with poor OHs with the accumulation of *Candida* sp. in dentures.<sup>16</sup>

The data obtained show that the mucosal lesions occur in patients using removable dentures, both partial and complete dentures. The patient's age varies, ranging from the youngest at the age of 26 to the oldest at 80 years past. Duration of use changes, ranging from 1 year to 32 years. Predilections from the above lesions also vary. Some are located on the alveolar ridge, the floor of the mouth, mucobuccal folds, palate, to the tongue. Hyperemia lesions dominated the type of lesion most experienced by patients diagnosed with denture stomatitis, which was suffered by 125 patients, followed by hyperplasia lesions experienced by 15 people, and one patient each with nodular and tumor lesion types.

### CONCLUSION

Mucosal lesions in patients with removable dentures, both removable partial denture, and full denture, are quite varied. Their presence is influenced by various factors, such as the length of use of dentures, denture conditions, and oral hygiene. Mucosal lesions evaluated in this systematic review were lesions of hyperplasia, hyperemia, tumors, nodules, and ulcerations.

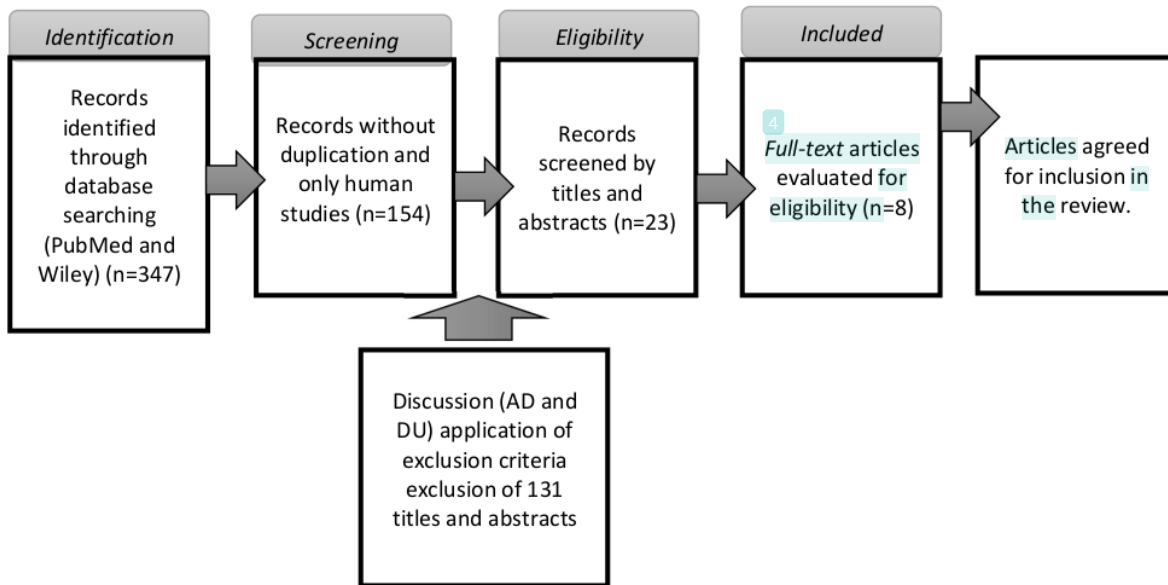
### REFERENCE

- Hug, S., Mantokoudis, D., & Mericske-Stern, R. (2006). Clinical evaluation of 3 overdenture concepts with tooth roots and implants: 2-year results. *International journal of prosthodontics*, 19(3).
- Rabiei, M., Kasemnezhad, E., Masoudi rad, H., Shakiba, M., & Pourkay, H. (2010). Prevalence of oral and dental disorders in institutionalised elderly people in Rasht, Iran. *Gerodontology*, 27(3), 174-177. <https://doi.org/10.1111/j.1741-2358.2009.00313.x>
- Dharmautama, M., Tetelepta, R., Ikbali, M., & Eka, A. (2017). Effect of mangrove leaves extract (*Avicennia marina*) concentration to *Streptococcus mutans* and *Candida albicans* growth. *J Dent Maxillofac*, 2(3), 1-5.
- Liberati, A., Altman, D. G., Tetzlaff, J., Mulrow, C., Gøtzsche, P. C., Ioannidis, J. P., & Moher, D. (2009). The PRISMA statement for reporting systematic reviews and meta-analyses of studies that evaluate health care interventions: explanation and elaboration. *Journal of clinical epidemiology*, 62(10), e1-e34. <https://doi.org/10.1016/j.jclinepi.2009.06.006>
- Davies, K. S. (2011). Formulating the evidence-based practice question: a review of the frameworks. *Evidence Based Library and Information Practice*, 6(2), 75-80.
- Durmaz EO. (2014). Denture induced fibroma. *Clin Exp Derm*. 39: 763-765.
- Bernardes, V. F., Diniz, M. G., Silva, J. C., Moraes, D. C., De Marco, L., Gomes, C. C., & Gomez, R. S. (2019). Lack of association between denture trauma and loss of heterozygosity confronts the proposed pathologic role of chronic mucosal trauma in oral carcinogenesis. *Journal of Oral Pathology & Medicine*, 48(5), 421-423. <https://doi.org/10.1111/jop.12846>
- Veena, K. M., Jagadishchandra, H., Sequria, J., Hameed, S. K., Chatra, L., & Shenai, P. (2013). An extensive denture-induced hyperplasia of maxilla. *Annals of medical and health sciences research*, 3(1a), 7-9. <https://doi.org/10.4103/2141-9248.121208>
- Azzi, L., Cerati, M., Lombardo, M., Pellilli, M., Croveri, F., Maurino, V., ... & Olszewska, M. (2019). Chronic ulcerative stomatitis: A comprehensive review and proposal for diagnostic criteria. *Oral diseases*, 25(6), 1465-1491. <https://doi.org/10.1111/odi.13001>
- Rashid, H., Sheikh, Z., & Vohra, F. (2015). Allergic effects of the residual monomer used in denture base acrylic resins. *European journal of dentistry*, 9(4), 614. <https://dx.doi.org/10.4103%2F1305-7456.172621>
- de Assis, E. M., Gomes, H. E., de Sousa, F. E. M., Brener, S., Leal, R. M., Souza, P. E. A., & Horta, M. C. R. (2019). Recurrent peripheral ameloblastoma in an elderly patient: A case report. *Gerodontology*, 36(1), 78-81. <https://doi.org/10.1111/ger.12377>
- Mamachan, P., Dang, V., Bharadwaj, N. S., DeSilva, N., & Kant, P. (2018). Chondroblastic Osteosarcoma—A Case Report and a Review of Literature. *Oncol Cancer Case Rep*, 4, 145.
- Maciel, C. M., Piva, M. R., Ribeiro, M. A. G., de Santana Santos, T., Ribeiro, C. F., & Martins-Filho, P. R. S. (2016). Methylene Blue-Mediated Photodynamic

*The Mucosal Lesions on Removable Denture Wearers: A Systematic Review*

- Inactivation Followed by Low-Laser Therapy versus Miconazole Gel in the Treatment of Denture Stomatitis. *Journal of Prosthodontics*, 25(1), 28-32. <https://doi.org/10.1111/jopr.12284>
14. Martori, E., Ayuso-Montero, R., Willaert, E., Viñas, M., Peraire, M., & Martinez-Gomis, J. (2017). Status of Removable Dentures and Relationship with Oral Candida-Associated Factors in a Geriatric Population in Catalonia. *Journal of Prosthodontics*, 26(5), 370-375. <https://doi.org/10.1111/jopr.12551>
  15. Tay, L. Y., dos Santos, F. A., & Jorge, J. H. (2015). Uncaria tomentosa gel against denture stomatitis: clinical report. *Journal of Prosthodontics*, 24(7), 594-597. <https://doi.org/10.1111/jopr.12248>
  16. Rautemaa, R., & Ramage, G. (2011). Oral candidosis—clinical challenges of a biofilm disease. *Critical reviews in microbiology*, 37(4), 328-336. <https://doi.org/10.3109/1040841X.2011.585606>

*The Mucosal Lesions on Removable Denture Wearers: A Systematic Review*



**Figure 1:** Article selection flow chart

*The Mucosal Lesions on Removable Denture Wearers: A Systematic Review*

Table 1: Descriptive data from the eight studies that reported the mucosal lesions as the manifestation of the patient with a removable denture

Author	Country	Sex; Age of Patients	Type of lesion	Clinical Examination	Diagnosis	Treatment	Type of denture	Prolonged use of denture
E.O. Durmaz (2014)	Turkey	F; 52 yo	Hyperplasia	Mucosal enlargement of 20x20 mm lower gingivolabial sulcus	Denture induced fibroma	Excision; new denture	full denture	Three years
Vanessa Fatima Bernardes, et al. (2019)	Brazil	F; 54 yo	Hyperplasia	Maxillary Alveolar ridge	Inflammatory fibrous hyperplasia	Excision	removable partial denture	-
		F; 65,67,70 yo		Maxillary Alveolar ridge				
		F; 64, 72 yo		Mandibular alveolar ridge				
		M; 62 yo		Maxillary Vestibulum				
		F; 61 yo		The floor of the mouth				
		F; 67 yo		Palate				
F; 46, 50,51 yo	Maxillary Alveolar ridge							
F; 50, 53, 56 yo	Mandibular Alveolar ridge							
Lorenzo Azzi et al. (2018)	Italia	F; 54 yo	Ulceration	Buccal, the floor of the mouth, lateral and ventral aspects of the tongue.	Oral Lichen Planus Erosive	Corticosteroid	full denture	-
Eliene Magda de Assis, et al. (2018)	Brazil	M; 79 yo	Nodule	1,5x1 cm nodule in the alveolar ridge of right mandibular canine-first premolar area	Recurrent peripheral ameloblastoma	Excision	full denture	12 years
Lidia Y. Tay et al. (2014)	Brazil	F; 64 yo	Hyperemia	Hyperemia of the palate under the denture	Denture stomatitis	DHE; antifungal	full denture	Four years
Elisenda Martori, et al. (2016)	Spain	63 F, 21 M; >60 yo	Hyperemia	Hyperemia of the palate under the denture	Denture stomatitis	DHE; antifungal	53 full denture, 31 removable partial dentures	≥15 years
Priya Mamachan et al. (2018)	India	M; 58 yo	Tumor	Swelling of the mucosa in the 11 to 25 regions with the size of 46,1x31,9x19,5 mm	Chondroblastic osteosarcoma	Resection	removable partial denture	18 years
Carolina Menezes Maciel, MSc., et al. (2014)	Brazil	30 F, 10 M; 26-80 years	Hyperemia	Hyperemia of the palate under the denture	Denture stomatitis	DHE; antifungal	removable partial denture dan full denture	1-32 years

# The Mucosal Lesions on Removable Denture Wearers: A Systematic Revi

---

## ORIGINALITY REPORT

---

6%

SIMILARITY INDEX

%

INTERNET SOURCES

6%

PUBLICATIONS

%

STUDENT PAPERS

---

## PRIMARY SOURCES

---

- 1** VANDANA KOKANE, NOOPUR KOKANE, Nitisha Saraf, Sayali Ukey, Shaishavi Satfale. "Attitude of dental interns, final year and third-year students towards their involvement in hospital work during COVID-19 pandemic in private dental colleges in Vidarbha, India", Research Square, 2021  
Publication 2%

---
- 2** Eliene Magda Assis, Hayder Egg Gomes, Felipe Esteves Milício Sousa, Sylvie Brener et al. "Recurrent peripheral ameloblastoma in an elderly patient: A case report", Gerodontology, 2019  
Publication 1%

---
- 3** Raili Ekelund. "Dental state and subjective chewing ability of institutionalized elderly people", Community Dentistry and Oral Epidemiology, 1989  
Publication 1%

---

4

Elcin Sag, Ahmet Serkan Kucukekenci, Durdu Karasoy, K. Vanc Akca, Steven Eckert, Murat Cavit Cehreli. "Comparative Assessments, Meta-Analysis, and Recommended Guidelines for Reporting Studies on Histomorphometric Bone-Implant Contact in Humans", The International Journal of Oral & Maxillofacial Implants, 2013

Publication

---

<1 %

5

Giorgio Lo Giudice, Romolo Fragola, Giovanni Francesco Nicoletti, Gabriele Cervino et al. "Facial Artery Myomucosal Flap vs. Islanded Facial Artery Myomucosal Flap Viability: A Systematic Review", Applied Sciences, 2021

Publication

---

<1 %

6

Bernd Turowski, Friedhelm E Zanella. "Interventional neuroradiology of the head and neck", Neuroimaging Clinics of North America, 2003

Publication

---

<1 %

7

Yee Shen Loo, Tse Yee Wong, Sajesh K. Veetil, Pei Se Wong, Divya Gopinath, Siew Mooi Ching, Rohit Kunnath Menon. "Antifungal agents in preventing oral candidiasis in clinical oncology: A network meta - analysis", Oral Diseases, 2020

Publication

---

<1 %

8

King, O.H.. "The frequency of pigmented nevi in the oral cavity", Oral Surgery, Oral Medicine, Oral Pathology, 196701

Publication

<1 %

9

Ingrid Andrade Meira, Lorena Tavares Gama, Daniela Almeida Prado-Tozzi, Mayara Abreu Pinheiro et al. "Speech in implant-supported and removable complete denture wearers: A systematic review", The Journal of Prosthetic Dentistry, 2021

Publication

<1 %

Exclude quotes On

Exclude matches < 5 words

Exclude bibliography On